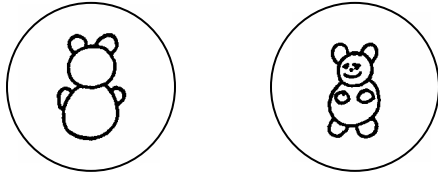
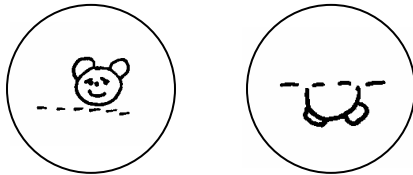


Activity 2: Gummi Bear Dissection

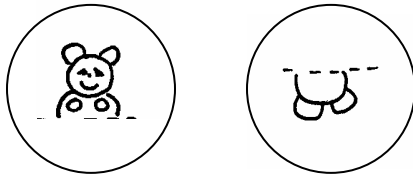
1. Dorsal and ventral



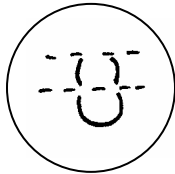
2. Anterior and posterior



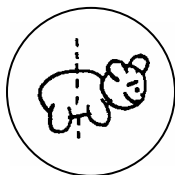
3. Cranial and caudal



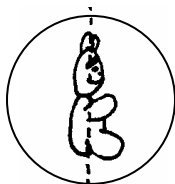
4. Proximal and distal




5. Transverse plane




6. Frontal plane



7. Median plane



8. Sagittal plane



9. May be any of the above.